

**MODERN CONCEPTION OF CANCER –
ITS HOMOEOPATHIC APPROACH
(CASE STUDIES)**

PROF. SANJOY BANERJEE – INDIA

drsanjaybanerjee@yahoo.co.in

TEN COMMANDMENTS

1. In Homoeopathy, cancer is called to be a chronic constitutional disease – caused by chronic miasms – Psora, Sycosis and Syphilis – in short, irritation, proliferation and destruction.

Homoeopathy plays an important role in prevention and management in all stages of cancer by the process of individualization

2. Clinical research shows hereditary background of cancer or Diabetes Mellitus or Tuberculosis or all three or other degenerative / proliferative chronic diseases etc. are held responsible for the inroad of cancer.

The newly discovered “**Carcinogens**” are the cause of formation of cancer cells. The three general classes of carcinogens are **Radiation, Chemicals and Viruses.**

3. The medical scientists are into research and experiments on “**Immuno Therapy**” to cure cancer but are yet to come up with thorough conclusion.

4. In Homoeopathic system of treatment, the medicine after succussion generates electrifying power in the light of modern science. During the process of preparation it evolves the power to meet the disease process. This is called “**High Light Isotopes**” by modern science.

5. The powerful homoeopathic medicine instead of causing any side effects works on the actual disease in particular and also activates the Immune System, so that it may get cured through antigen-antibody. On the contrary, in cases of chronic reversible diseases deep acting homoeopathic anti-miasmatic medicine will help to cure slowly and gradually by the mutagenic power of medicine or by the process of Reverse mutation in reversible cases.
6. It may be stated that, modern school of life science admits when the functions of a minute chemical particle having favourable functions reaches the chromosomes and may have fruitful effect, likewise (electro magnetic change effect) change the genetic system through haemostasis process hence it is not too difficult to accept the fact that Homoeopathy is the best possible medication that may be given to a cancer affected individual. A fact that is still to be searched by the medical scientists.
7. In Cancer – Homoeopathic Medicine works with promising result after and during conventional therapies (clinical research study).
8. In all chronic cases, the old suppressed symptoms should come out in the surface following betterment of internal and mental symptoms (Hering's Law of Cure)
9. In conclusion, suitable anti-Psoric medicine to be given to prevent relapses of cancer and other chronic incurable diseases.
10. Vegetarian diet with high fluid intake is advisable to eliminate the toxins from the body.

CANCER

Prof. Sanjoy Banerjee.India

[\(drsanjaybanerjee@yahoo.co.in\)](mailto:drsanjaybanerjee@yahoo.co.in)

Background

Homoeopathic therapy showed anticipated results while modern conventional therapies fails to do any better in cancer.

In homoeopathy Cancer is called chronic disease caused by chronic miasms – Psora, Sycosis and Syphilis.

Homeopathy plays an important role in prevention and management after and during surgical, radio and chemotherapy by increasing immune system through constitutional anti-miasmatic medicine on the process of individualization.

Case Summary

1. Prevention of hysterectomy and Cancer Cervix-(CIN-III)



“I am very much depressed and scared of operation and Cancer”.
“Can you help me by Homoeopathic treatment to prevent Cancer and Operation ?”

Mrs. B. B. 46 yrs.
2nd June – 1990 (Australia)

Before Homoeopathic Treatment

P.C.

1. Chronic leucorrhoeal and bloody discharges
2. **Sense of something in the left lower abdomen- travels to other parts of abdomen. (fixed idea)**
3. H/O Recurrent cystitis.
4. Mentally – irritable, suppresses anger, nervous, fearful, jealous.

P.H.

1. Asthma, Bronchitis, Scarlet fever.
2. Skin rashes ++ treated by local medication
3. Warty growths in lower abdomen and other parts – Cauterised.
4. Vaccinosis ++

F. H.

1. HTN, Emphysema, Psoriasis, Arthrites, Neurosis
2. **Cancer, cervicitis with abnormal cells in the Cx**

Laboratory findings :-

Report of Dr. Paul A. Stokes cc P : stokes
(Mary borough, Australia – Date – 02.05.90)

Summary

Cervical biopsy : Koilocytotic atypia and moderate dysplasia-CIN-II
Cervical curettings : Chronic Cervicitis and Focal koilocytosis.

Medicine – (02.06.90)

Thuja – 2c (Fixed Idea, Cervicitis, Cystitis + + Vaccinosis, Warts, and important Family History)

Remarks- (01.08.90)

Betterment of mental and some physical symptoms, burning urination, discomfort in abdomen etc.

Thuja – 1M

Remarks – 25. 09 .90

Urinary bladder weakness (old symptoms)

2nd Biopsy – (15.08.90) / 3rd Biopsy (23.11.90)

Cx Section Show – (CIN –I-II)

Show little change in the appearance since last biopsy, Normal endocervical & ectocervical epithelium)

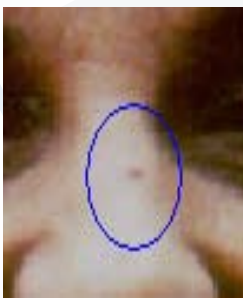Thuja 1M (25.09.90)

Thuja 10M (05.01.91)

Remarks as on - 03 . 03 .91

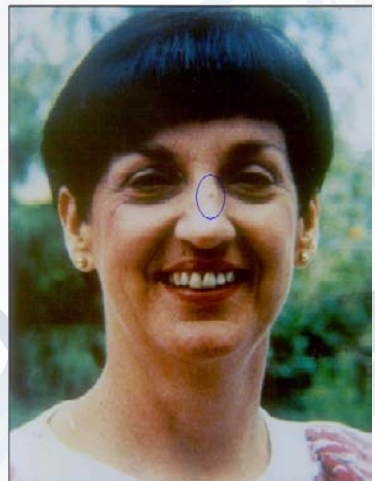1. Appearance of Cauliflower like growth over nose
2. Progressive improvement of physical and mental symptoms.

No Medicine.



March 1991

**During Homoeopathic Treatment
with warty growth over nose**



4th Biopsy (10.04.91)

Summary

- 1) **Cervical Curettings** :- No Significant pathology.
- 2) **Cervical Biopsy** :- Moderate squamous dysplasia (**CIN-II**). No Koilocytosis, chronic cervicitis.

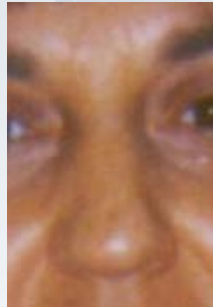Observation :-

There were no reappearances of vaginal discharges even after change in the 4th biopsy report from CIN-I-II to CIN-II. Previously, before homoeopathic treatment she had discharges with biopsy report CIN-II

Conclusion & Discussion :-

Clinically and in support of the investigation reports, and as per opinion of W.H.O. – 1975. This case appeared to be incurable (CIN-II-moderate dysplasia – **Precancerous stage**), and she was advised to have total hysterectomy to prevent her from **Cancer Cx (CIN-III-severe dysplasia to Carcinoma in situ)**.

Mrs. B.B. was saved from a gloomy prognosis by avoiding operation and by taking homoeopathic treatment on the principles of **Similia-Similibus-Curentur** by the process of **individualisation**.



October 1991
After falls off of warty
growth over nose

Clinical observation of the patient at Brisbane, Australia on 24.05.91 and on 01.05.94

“I am fine, no complain”.

“Cauliflower like growth over nose falls off at the end of March,1991 (which persists for about 3 months)”--- Mrs. B.B.

Advised : Not to go for biopsy again .

Psorinum 10 M one dose given to prevent relapses of cervical problem and remission of slight skin rash.

Metastatic adeno-carcinoma of Gall Bladder

– Staphisagria etc.

Presented by **Prof. Sanjoy Banerjee India**

(drsanjaybanerjee@yahoo.co.in)

“ I am having abdominal pain, emaciation , hair loss, blackish skin, low platelet count during the course of chemotherapy after cholecystectomy”

I want to get rid of all the complaints by homoeopathic treatment along with chemotherapy ; Will it be possible to treat me ? If so please do.”

Mrs. S.B. age 50 yrs. Kolkata, India



**After chemotherapy
Before homoeopathic treatment**

Cancer G.B. cured by chemo and homoeotherapy

Mrs. S. B. an **introvert** lady had above complaints during the course of fifty one shots of chemotherapy (flurocil, mitomycin etc. for about one year.)

P.H. : Eczema, Tooth cavities


F.H. : D.M. Bone T.B., HTN, Eczema.

Biopsy of G. B. operation part (23.04.94)

“ Metastatic adeno-carcinoma of Gall Bladder”

She was with homoeopathic treatment along with chemotherapy and shows progressive improvement of all gastric and other complaints following appearances of skin rashes (old symptoms). She is now living normal life as a house wife and used to visit for some rheumatic problem, lastly she came in Feb' 10.

Medicine :- Staphisagria, Acid Nitric, Nux Vom etc. as per change of symptom due to suppressive mode of treatment by chemotherapy



**After observations for six months of
homoeopathic treatment**

Important observation :

Homoeopathic treatment can be done even with chemotherapy for better result.

Finally she was given Psorinum followed by Lycopodium to prevent chances of relapses

Discussion : Hepato protective effect of homoeopathic medicine and herbal drug

Microanatomical observations revealed that centrilobular necrosis in the liver after the repeated doses of C.C.I. was markedly reduced in rat receiving homoeopathic medication (Lycopodium – 2c or Chelidonium-mother tincture in two groups) along with C.C.I infections , but the functions are dose dependent (reasearch study made by Dr. S. S. Sur, C.U. 1999. This experiment proved by Khuda Buksh of Kalyani University, India, that above cited drug can act as hepato protective).

Cancer of brain – Staphisagria Spindle cell tumor – Malignant

Presented by **Prof. Sanjoy Banerjee**, India
drsanjaybanerjee@yahoo.co.in



Mr. Das, 59 yrs

Case Study:-

This case was referred by his relative – a case of Cancer Urinary Bladder, who got cured by homoeopathy 20 years back.

Mr. Das, 59 yrs was admitted in the hospital.

Discharge Summary –

Christian Medical College, Vellore – 4
Neurosurgery Unit 1

Diagnosis – Right cerebellar spindle cell tumor - Malignant

History –Presented with progressive headache and vomiting –2weeks Difficulty in walking with tendency to fall to the right side, no h/o loss of consciousness, seizures or limb weakness.

C.T Scan of brain 20.10.06 –(Before operation) Medi scan
– Durgapur

Impression– a well defined mass in the posterior fossa on the right side, measuring about 36x41x33mms. The lesion was hypo intense on T1 and iso intense onT2 weighted images and had a thick enhancing rim. There was perilesional edema and mass effect on the adjacent cerebellar hemisphere, pons and fourth ventricle which was partly affected.

Operation – 26.10.06

Biopsy CMCH Vellore 30637/06

Spindle cell tumor – probably malignant

Condition at discharge – afebrile, ambulant. His headache had subsided completely.

C.T. Scan of brain – 03.11.06 (after operation)

Findings – right occipital craniectomy noted, scalp edema noted in the operative site, no residual enhancing tumor noted. Mild hypo density noted in right inferior cerebellum-post operative edema, rest nil significant.

Patient's history & treatment

Patient was unable to visit my chamber. His son came with all the reports and complaints of his father. Afterwards patient came alone after improvement by homoeopathic treatment.

Complaints as on 25.11.06

Mr. Das was addicted to **chewing tobacco**. He had headache, vomiting, weakness in right arm, speech defect, disbalance on walking, lack of concentration and in coordination.

P.H - Bleeding piles, **rash in back of head & itch**, chickenpox

F.H - Cancer lung and urinary bladder

Medicine Symptomatic in L.M & Centesimal potency.

Staphisagria, Thuja, Carcinisin, Causticum

Intercurrent – Coniun Mac

C.T. Scan of brain – 20.11.2007

A year after operation M.D.C.T features – ill defined hypo dense non enhancing area in the right cerebellar hemisphere region with evidence of surgery. Post operative glial changes vs. any other pathology.

Patient feels better excepting slight vertigo and indigestion as per report upto 27.03.09

Complaints as on 20.01.10

Betterment in vomiting, headache, weakness in right arm.

Slight speech difficulty persisting.

Rash appears at the back & right side of head and neck (old symptom) - Rhus Tox 12c - 1 dose.

At present he is very cheerful having normal life.

Excepting slight vertigo for which Conium M. 1M / 1 dose given.

C.T. Scan of brain – 02.03.2010 EKO DIAGNOSTIC

On comparison with previous CT Scan done on 20.11.2007, No significant change is seen. No recurrent or residual **SOL** is noted presently

Report 07.04.2010 – Vertigo and speech defect better. Can do house hold work – gardening etc. Skin eruption appears. No medicine.

As a conclusive treatment he needs suitable anti-psoric medicine to prevent relapse.

Throat Cancer

- a relapsed case after radio therapy cured by homoeo-therapy-Phytolocca etc.-

Presented by **Prof. Sanjoy Banerjee**, India
drsanjaybanerjee@yahoo.co.in

Case Summary :-

Mr. S.M.M. 83 yrs. reported that he had improvement for certain period after 30 shots of **Cobalt ray** but relapsed. He had stiching pain in right side of throat shoots to right ear, dysphagia etc.

P.H. Typhoid, M.Malaria, **Parotitis, Scabies**

F.H. Asthma, **Cancer.**

Biopsy (06.08.07)

Inference : Moderately differentiated squamous cell carcinoma (rt. Pyriform fossa)

Gene test : Shows apparently normal karyotype. Philadelphia chromosome not seen.

Note: Identical case of throat cancer shows abnormal chromosome pattern, 40% cells shows – gap or deletion in chromosome No. 4 (24.11.01)

Medicine : Phytolocca, Radium Brom, Carcinosis, Psorinum etc.
According to the change of symptoms which are suppressed by radio therapy treatment.

Out come : Relapse case of cancer after ray treatment can be well managed by homoeopathy treatment by its immuno modulatory effect.

Discussion : The effect of reducing radiation damage at the chromosomal level can be modified with homoeopathic medicine. Homoeopathic treatment can be done with or after chemotherapy or radiation. The efficacy of some homoeopathic drugs and medicine in reducing radiation damage at the chromosomal level are Arnica-200, Ruta g – 30, X-ray 30, Hypericum- 30, (ref. Khuda Buksh etal 1982/2001–25th March)

Above cited reports and references confirmed that homoeo-medicines and homoeotopathy can antidote the drug induced or iatrogenic disorders and syndrome (reversible)-
Like your life.

Cancer of left breast – metastasis to liver and ribs. Surgical therapy fails to give better result than Homoeopathic Therapy.

Presented by **Prof. Sanjoy Banerjee**, India
drsanjaybanerjee@yahoo.co.in

A cured case by Arsenic Album. History – Mrs. S.C, 61 years reported on 30.04.93 with history of left breast lump. (Cancer operated on 11th July 1991)
P.C - Periodical crampy pain in upper abdomen and tenderness breathlessness. restless, anxiety and apprehending death as there was no relief with strong analgesic. Pain worse midday and mid night cachexia, thirst little at a time, nausea & vomiting. Weakness. Vertigo with moderate appetite. History of burning urine, warts on left shoulder. Mentally irritable specially on any disorder.

P.H - Gastric Ulcer, fungal infection, TB, Colectomy. HTN, Malaria – h/o fever worse at mid night.

F.H - HTN-rheumatism, kidney cancer

C.F - Liver enlarged, hard and tender
Edema left arm due to operation of axillary lymph gland during Mastectomy.

Micro Section shows infiltrating duct carcinoma with dense stromal sclerosis. **Bone scintigraphy** - 02.08.91 & 27.08.92

Comment - Increased and abnormal uptake in the rib and scapula. Could be due to metastasis.

U.S.G upper abdomen - 02.04.93

Impression – Hepato megaly with multiple nodules.

Treatment 30.04.93 Arsenic Album in LM potency. The striking features was **the sensitivity to any disorder** even with low vitality, anxiety mid day midnight aggravation, restlessness, thirsty, h/o burning urination, nausea & vomiting.

10.12.93 - Much better in all respect following appearance of reddish moles 2months with itch.

Important observation Clinically and in support of the investigation reports, this case appeared to be an advanced malignancy of left breast metastasis to liver and ribs. Considering the extreme cachexia, weakness enlarged liver knowledge of pathology suggested that this case was incurable. The result after treatment shows the efficacy of homoeopathic medicine even in incurable case is simply marvelous.



Mrs. S.C, 61 years